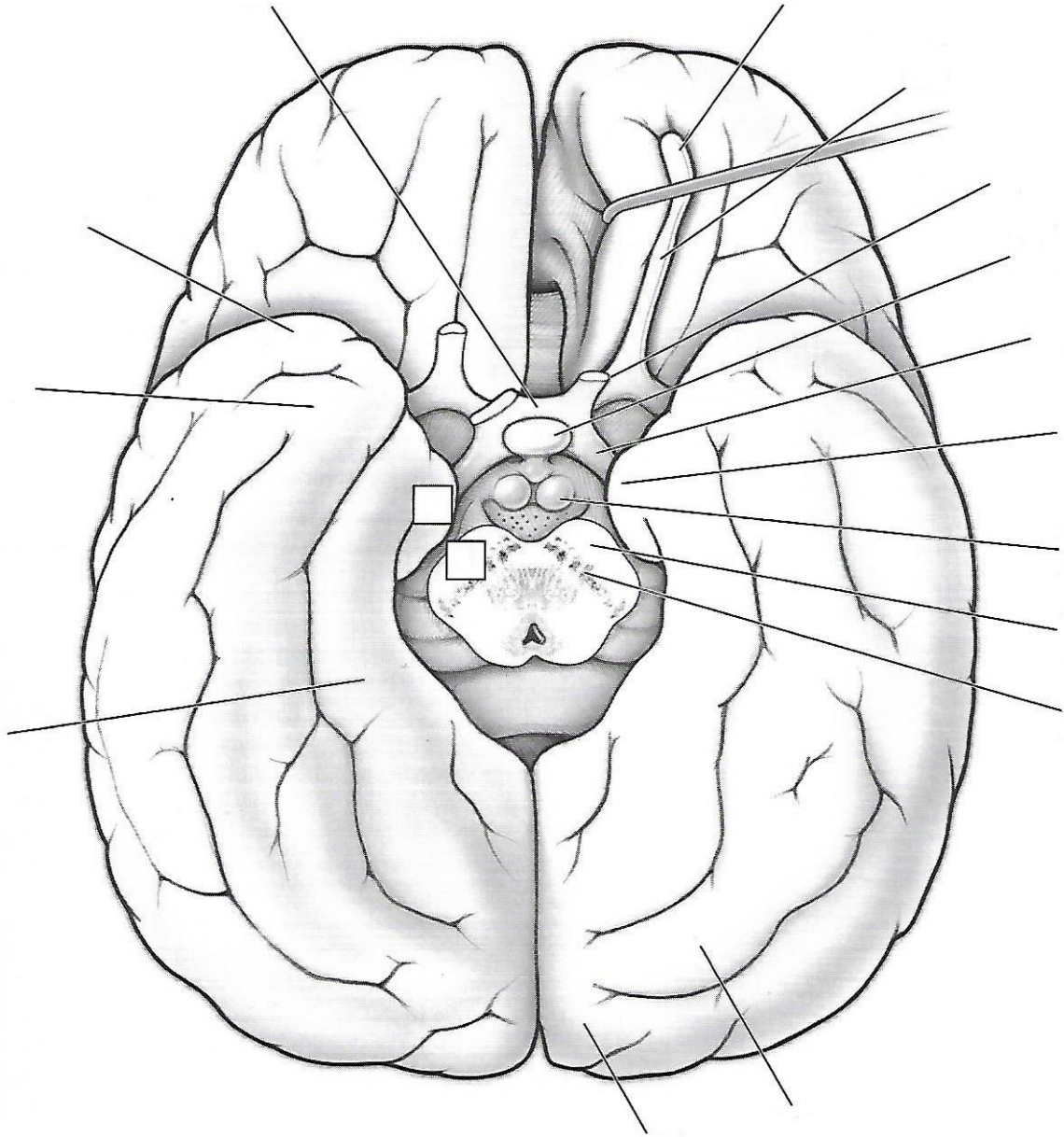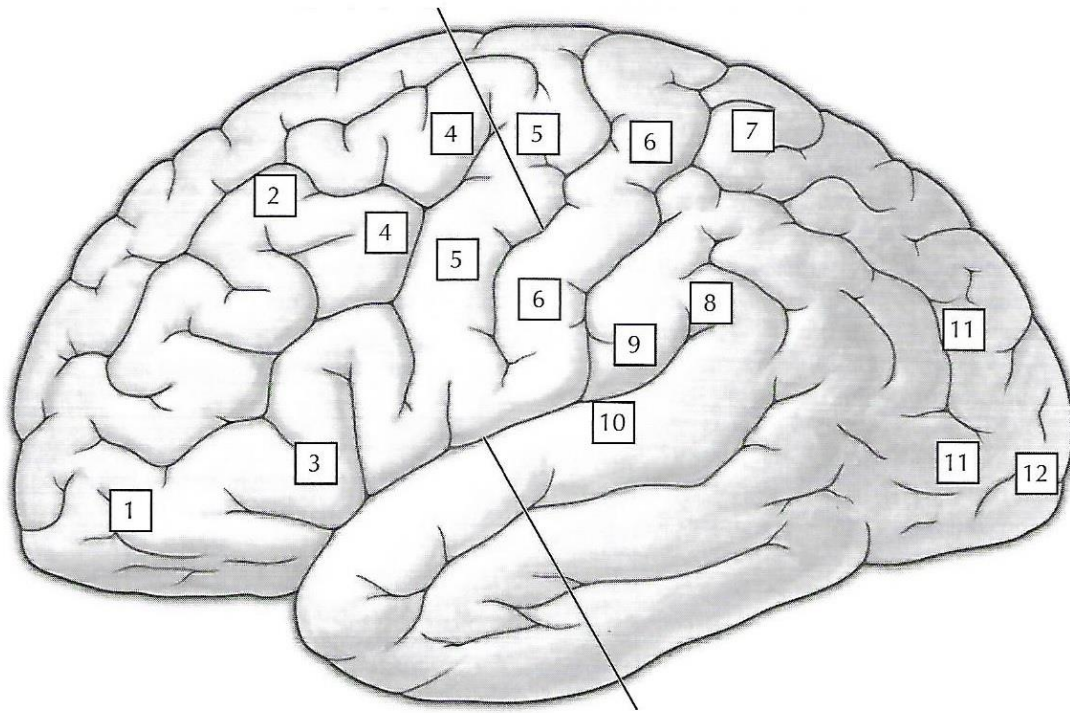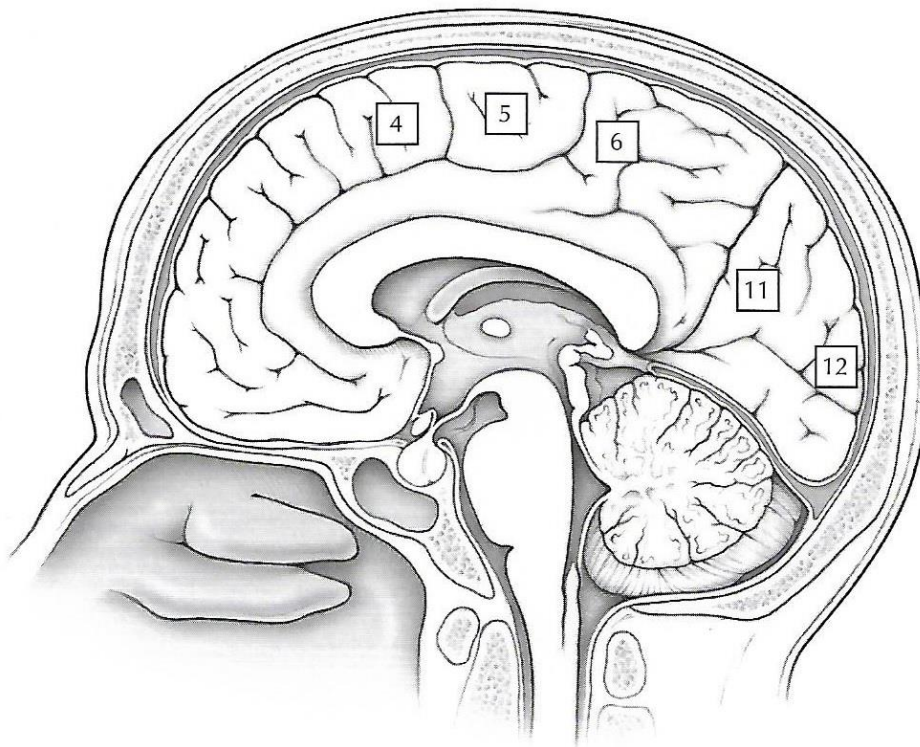
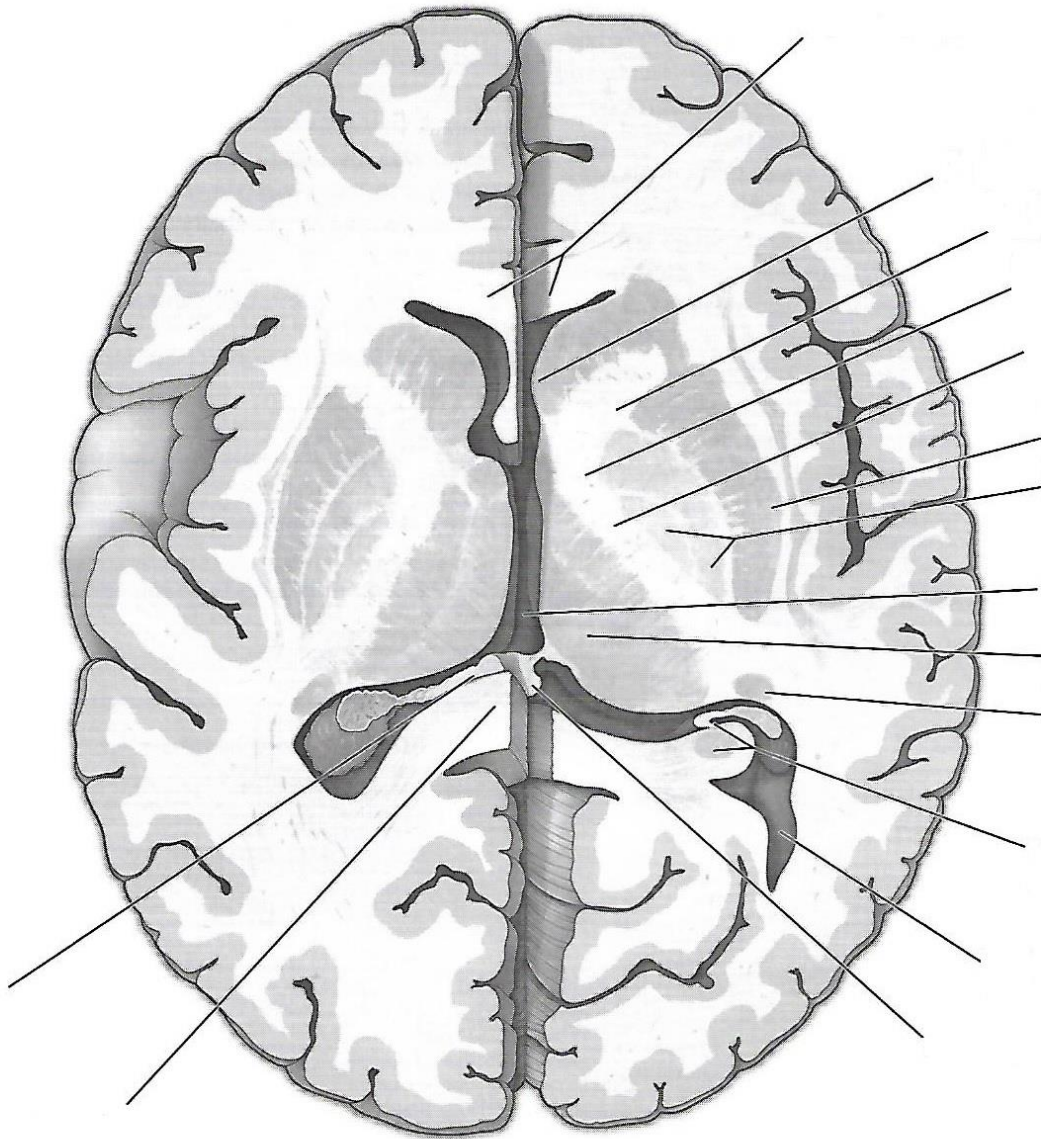


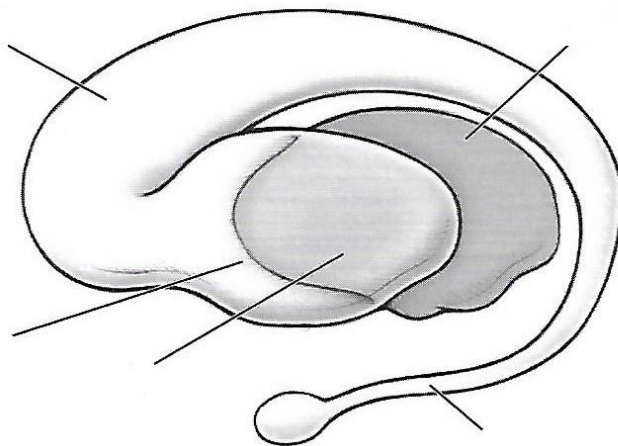
A. Lateral view of forebrain



B. Medial (midsagittal) surface of the brain in situ



A. Axial sections showing the basal ganglia



B. Schematic 3D depiction of the basal ganglia

