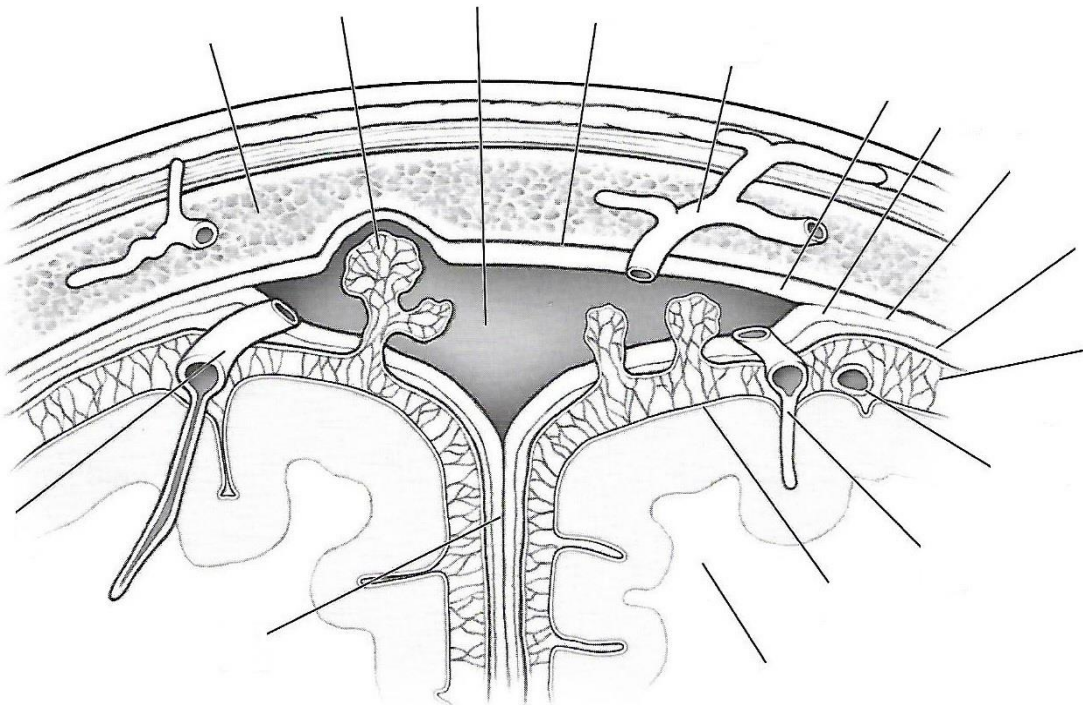
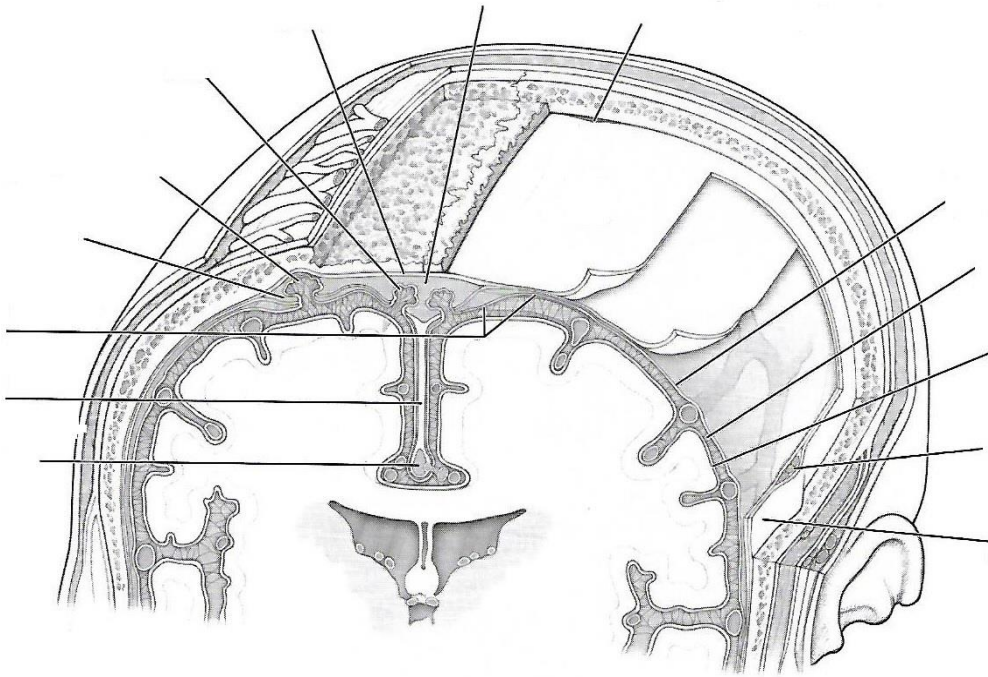
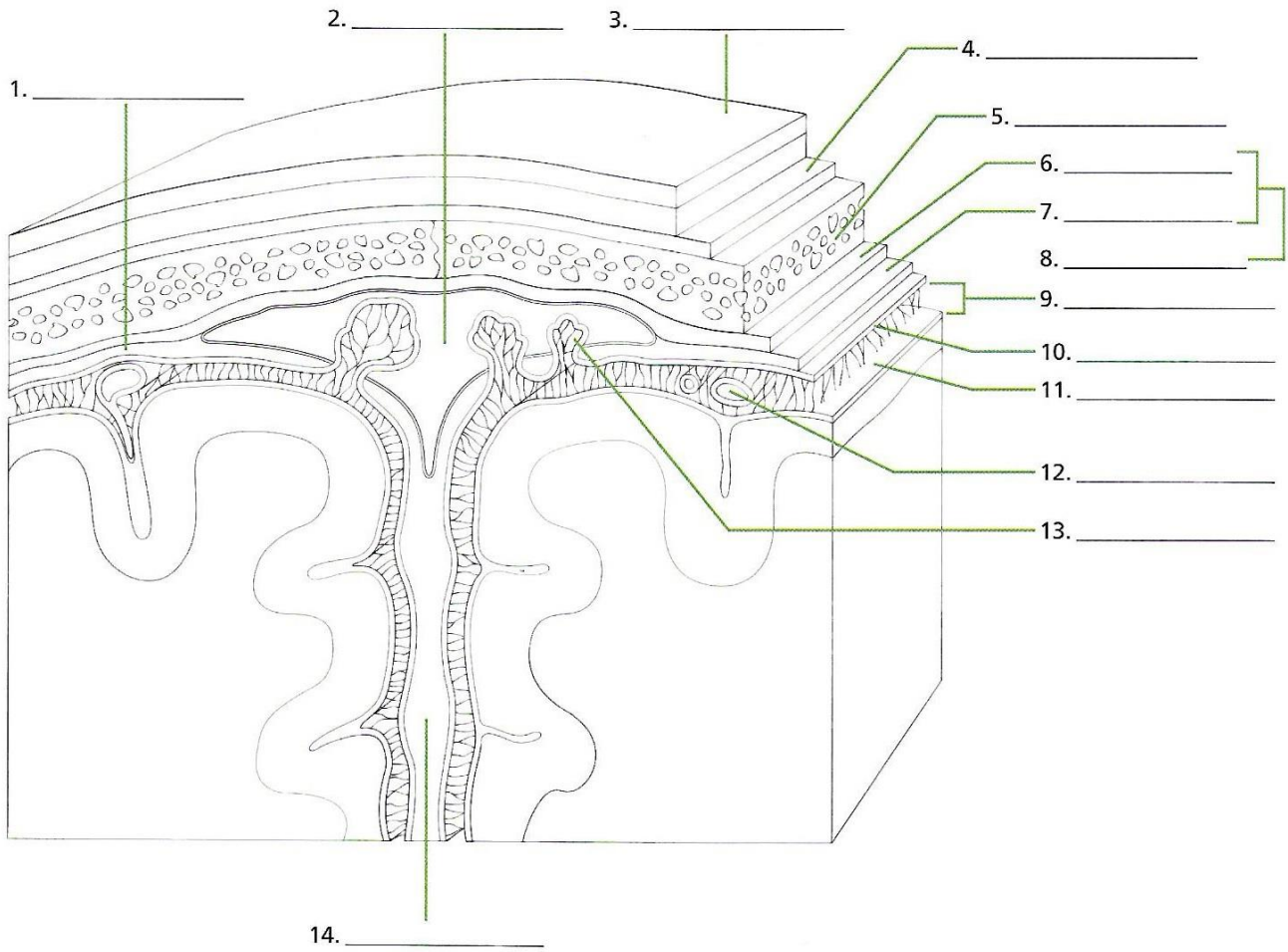


MENINGES Y CIRCULACIÓN DE LÍQUIDO CEFALORRAQUÍDEO



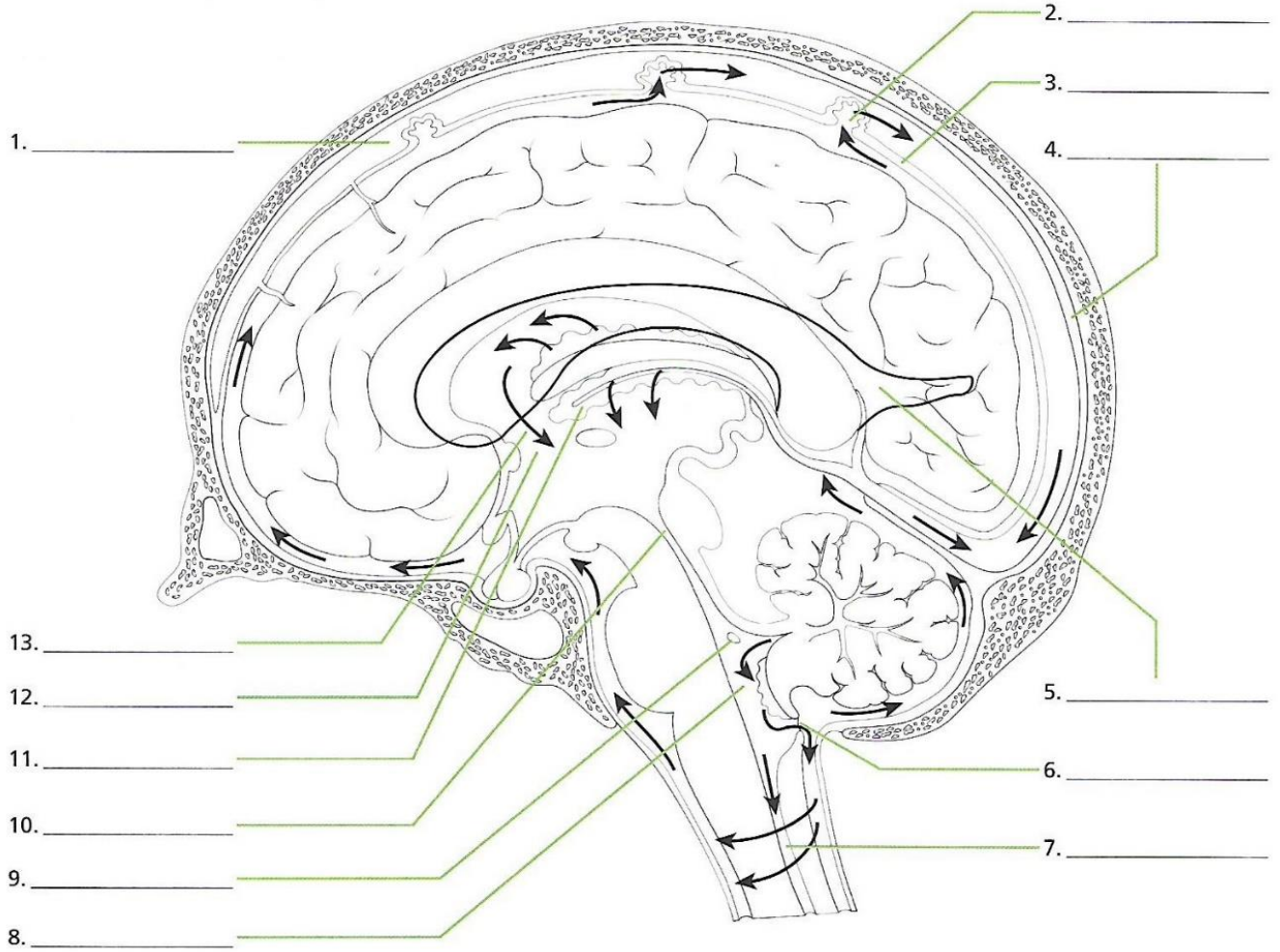
MENINGES Y CIRCULACIÓN DE LÍQUIDO CEFALORRAQUÍDEO



Answers

1. subdural space, 2. superior sagittal sinus, 3. skin of scalp, 4. perosteum, 5. pia mater, 6. bone of skull, 7. meningeal layer, 8. dura mater, 9. subarachnoid space, 10. arachnoid mater, 11. falx cerebri, 12. blood vessel, 13. arachnoid villus, 14. falx cerebri

MENINGES Y CIRCULACIÓN DE LÍQUIDO CEFALORRAQUÍDEO



Answers

1. superior sagittal sinus, 2. arachnoid granulation, 3. subarachnoid space, 4. meningeal dura mater, 5. right lateral ventricle, 6. median aperture, 7. central canal, 8. fourth ventricle, 9. lateral aperture, 10. cerebral aqueduct, 11. choroid plexus, 12. third ventricle, 13. interventricular foramen