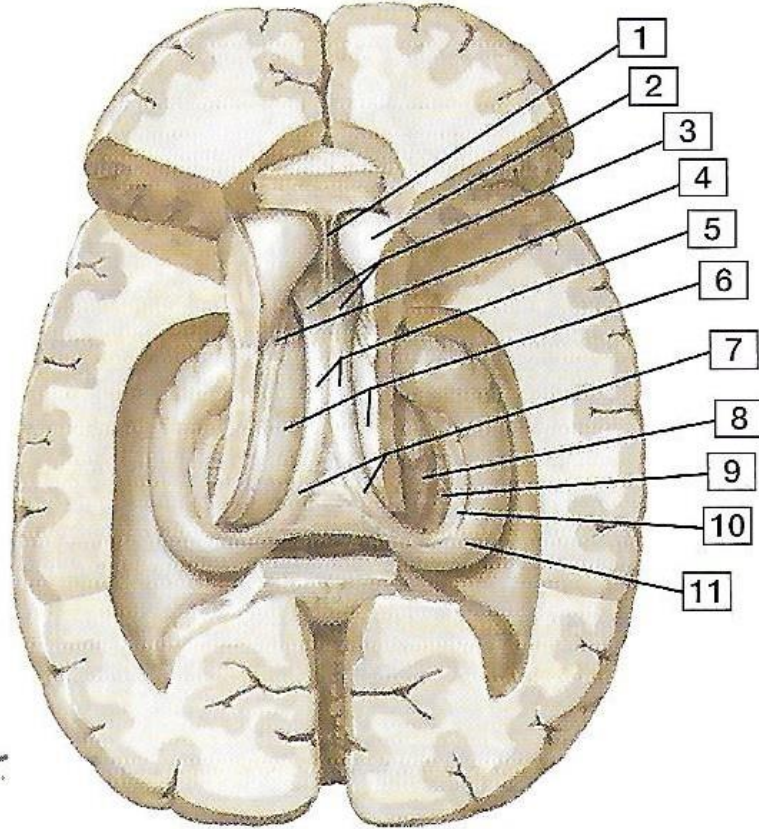
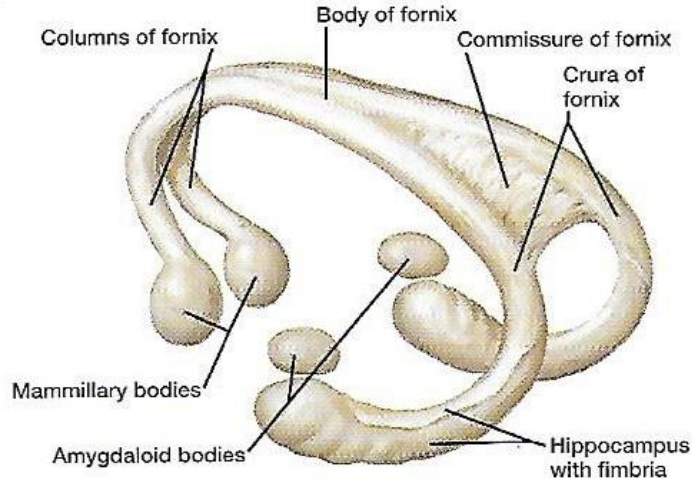


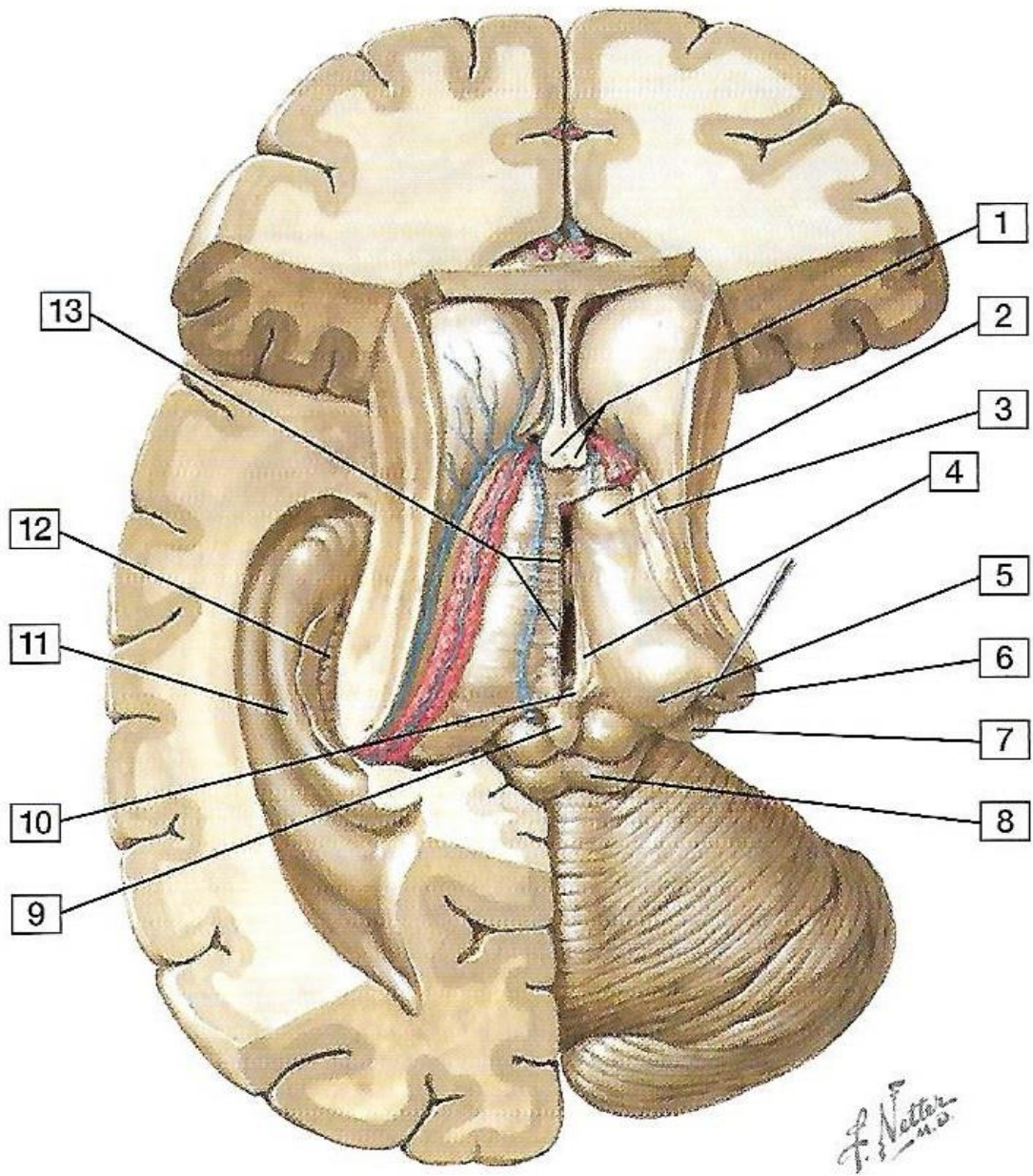
A. Dissection of the hippocampal formation and fornix

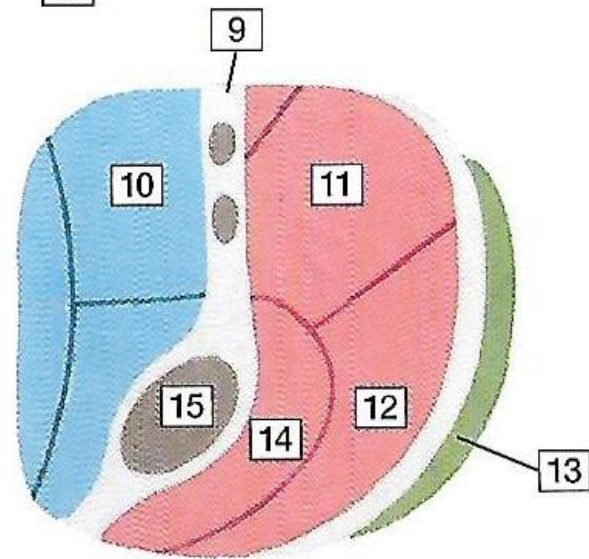
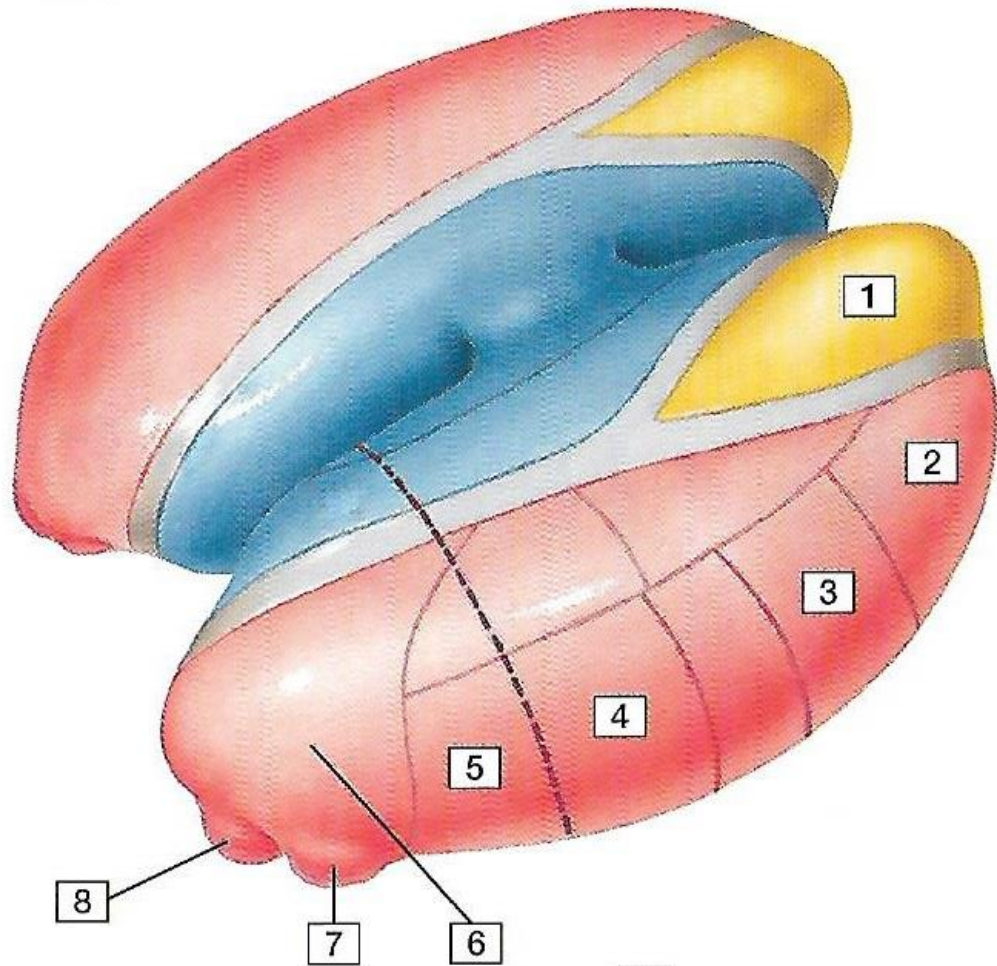


F. Netter M.D.
with
J. Perkins
MS, MFA

B. 3-D reconstruction of the fornix







F. Netter M.D.
with
J. Perkins